



THE ANNALS OF THORACIC SURGERY



Urgent Contralateral Pneumonectomy After Single Lung Transplantation for Lymphangioleiomyomatosis

Luca Voltolini, Luca Luzzi, Piero Paladini, Bonizella Biagioli, Paola Rottoli and
Giuseppe Gotti

Ann Thorac Surg 2005;80:2349-2351

DOI: 10.1016/j.athoracsur.2004.07.089

The online version of this article, along with updated information and services, is
located on the World Wide Web at:

<http://ats.ctsnetjournals.org/cgi/content/full/80/6/2349>

The Annals of Thoracic Surgery is the official journal of The Society of Thoracic Surgeons and the Southern Thoracic Surgical Association. Copyright © 2005 by The Society of Thoracic Surgeons. Print ISSN: 0003-4975; eISSN: 1552-6259.

established metastatic disease and precluded any further attempts of resection. In all three patients, the findings and results from EUS and FNA changed the management of these patients.

In conclusion, this case series of 3 patients demonstrated the ability of EUS-guided FNA to detect and pathologically confirm locoregional lung cancer recurrence at the surgical bed and mediastinal nodes. As such, this is the first report on the use of EUS-FNA for work-up of lung cancer recurrence. Further study is necessary to characterize its efficacy and safety, especially regarding the FNA of recurrence in the surgical bed.

References

1. Baldini E, DeCamp MM, Katz M, et al. Patterns of recurrence and outcome for patients with clinical stage II non-small-cell lung cancer. *Am J Clin Oncol* 1999;22:8–14.
2. Pairolero PC, Williams DE, Bergstralh EJ, Piehler JM, Bernatz PE, Payne WS. Postsurgical stage I bronchogenic carcinoma: morbid implications of recurrent disease. *Ann Thorac Surg* 1984;38:331–8.
3. Younes RN, Gross JL, Deheinzeln D. Follow-up in lung cancer. How often and for what purpose? *Chest* 1999;115:1494–9.
4. Curran WJ, Herbert SH, Stafford PM, et al. Should patients with post-resection locoregional recurrence of lung cancer receive aggressive therapy? *Int J Radiat Oncol* 1992;24:25–30.
5. Colice GL, Rubins J, Unger M. Follow-up and surveillance of the lung cancer patient following curative-intent therapy. *Chest* 2003;123:272S–83S.
6. Watanabe Y, Shimizu J, Oda M, Tatsuzawa Y, Hayashi Y, Iwa T. Second surgical intervention for recurrent and second primary bronchogenic carcinomas. *Scand J Thor Cardiovasc Surg* 1992;26:73–8.
7. LeBlanc JK, Espada R, Ergun G. Non-small cell lung cancer staging techniques and endoscopic ultrasound. Tissue is still the issue. *Chest* 2003;123:1718–25.
8. Furuta M, Nozaki M, Kawashima M, et al. 99m Tc-MIBI scintigraphy for early detection of locally recurrent non-small cell lung cancer treated with definitive radiation therapy. *Eur J Nucl Med Mol I* 2003;30:982–7.
9. Wallace MB, Silvestri GA, Sahai AV, et al. Endoscopic ultrasound-guided fine needle aspiration for staging patients with carcinoma of the lung. *Ann Thorac Surg* 2001;72:1861–7.

Urgent Contralateral Pneumonectomy After Single Lung Transplantation for Lymphangioleiomyomatosis

Luca Voltolini, MD, Luca Luzzi, MD,
Piero Paladini, MD, Bonizella Biagioli, MD,
Paola Rottoli, MD, and Giuseppe Gotti, MD

Thoracic Surgery Unit; Respiratory Diseases Section,
Department of Immunology and Clinical Medicine;
Cardiothoracic Intensive Care Unit, University Hospital of
Siena, Siena, Italy

Left single lung transplantation in a 33-year-old woman affected by end-stage lymphangioleiomyomatosis was

Accepted for publication July 19, 2004.

Address correspondence to Dr Luzzi, Thoracic Surgery Unit, Viale Bracci
14, Siena, 53100 Italy; e-mail: luzzi.luca@virgilio.it.

complicated by spontaneous and diffuse bleeding from the right lung at the end of the procedure. The right lung was completely deteriorated and the only option to stop the bleeding was a right pneumonectomy. At 14 months after transplantation, the single allograft showed good lung function with acceptable volumes. Single lung transplant and contralateral pneumonectomy can be considered a safe procedure in case of complications related to native lung either in case of lymphangioleiomyomatosis than for other lung diseases (emphysema, cystic fibrosis).

(*Ann Thorac Surg* 2005;80:2349–51)

© 2005 by The Society of Thoracic Surgeons

Lymphangioleiomyomatosis (LAM) is a rare disease of unknown origin that afflicts young women in child-bearing age and usually leads to progressive deterioration of lung function and eventual death from respiratory failure [1]. It is characterized by a proliferation of hamartomatous smooth-muscle cells preferentially along the bronchovascular structures, resulting in obliteration of the airways and the consecutive development of cystic air spaces [2]. Lung transplantation has emerged as a viable treatment option for patients with end-stage LAM [3]. Patients affected by end-stage LAM often require treatment by pleurectomy because of recurrent pneumothorax or chylothorax that are not affected by other more conservative forms of treatment [4, 5]. Patients who undergo pleurectomy represent a group at risk of bleeding during lung transplant, especially when cardiopulmonary bypass (CPB) is required [6]. We report a case of a patient affected by LAM who underwent successful single lung transplantation followed by an urgent contralateral pneumonectomy because of massive intraparenchymal bleeding with an excellent outcome.

A 33-year-old woman who was diagnosed with LAM was assessed and accepted for pulmonary transplantation in December 2002. Her medical history was remarkable for numerous bilateral recurrent pneumothoraces that were successfully treated only by a partial pleurectomy on the left side and a total pleurectomy (including the mediastinal pleura) on the right side. Physical examination revealed a debilitated patient, not ambulatory, dependent on 6 to 8 L/min of nasal oxygen and hypercapnic (70 to 80 mm Hg of carbon dioxide tension). Pulmonary function tests showed a severe obstructive defect with a forced expiratory volume in one second of 0.31 L (12% of predicted), a forced vital capacity of 0.8 L (25% of predicted) and a forced expiratory volume in one second/forced vital capacity ratio of 0.38. The computed tomographic scan of the chest performed in July 2002 in another hospital showed diffuse cystic degeneration of the lungs (Fig 1). Echocardiography revealed normal left ventricular contractility, severe global right ventricular hypokinesia and a moderate tricuspid regurgitation. Right heart catheterization revealed a pulmonary artery pressure of 85/40 with a mean of 60 mm Hg, a cardiac output of 3.4 L/min, and a pulmonary vascular resistance of 3.8 Wood units. Therefore the necessity to perform the

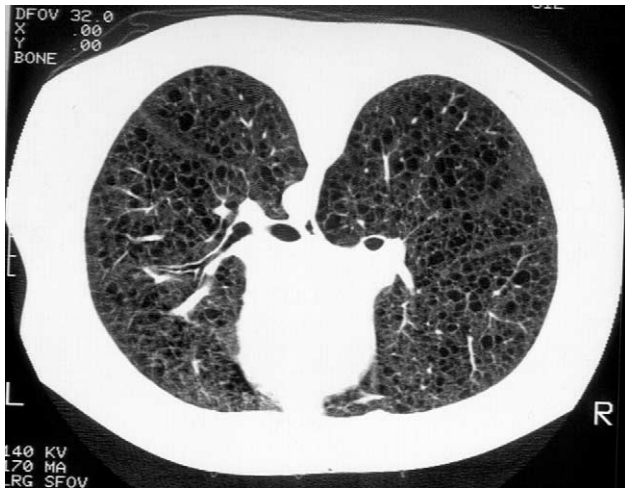


Fig 1. Pretransplant computed tomographic scan of the chest.

lung transplantation on CPB seemed very likely. The patient was listed for a left single lung transplantation, because free from pulmonary infection, a double lung transplantation was considered to be too risky after the previous total pleurectomy. In February 2003, 6 months after the first assessment, a suitable left lung was obtained by distal procurement from a 35-year-old female donor (165 cm height and 60 kg weight), who was a victim of a car accident. The lung was perfused with 3 liters antegrade and 1 liter retrograde of Celsior pneumoplegic solution and transported on ice. At that time the recipient was hospitalized and required noninvasive mechanical ventilation for deterioration of her lung function with carbon dioxide tension of 90 mm Hg.

A left posterolateral thoracotomy was performed while the femoral vessels were exposed. There were dense pleural adhesions, which were freed by electrocautery before starting CPB. While clamping the left pulmonary artery, a drop in venous oxygen saturation, an elevation of the pulmonary artery pressure with abnormal distension of the right ventricle, and systemic hypotension developed. Partial femoral-femoral CPB was then commenced. The left lung was removed and a conventional left lung implantation with bronchial, pulmonary arterial and left atrial anastomosis was performed. After reperfusion, the patient was weaned from CPB without difficulty. The total ischemic time was 170 minutes and the CPB time was 160 minutes. A substantial amount of blood started to profuse rapidly from the right side of the double lumen endotracheal tube. Bronchoscopy was immediately performed showing a persistent and copious bleeding from the periphery of the right lung. After aspirating about 1.5 L of blood and without any sign of stopping, despite adrenalin and tranexamic acid instilled in the tracheal tube, the patient was positioned into the left semi-lateral position and a right anterolateral thoracotomy was performed. The right lung had completely deteriorated (Fig 2) and a right pneumonectomy was the only option. The vascular structures were ligated and divided, and the right bronchial suture was performed by staple reinforcement by some interrupted monofilament

polypropylene sutures and then buried beneath mediastinal tissues.

The pleural space was irrigated with aqueous Betadine solution. The chest was closed over a single basal drainage tube (Redax, Modena, Italy) that had been connected to a balanced drain. Immunosuppressive therapy consisted of routine triple therapy with cyclosporine, azathioprine, and prednisone. Antimicrobial prophylaxis was based on vancomycin, ceftazidime, and fluconazole. The right chest tube was not removed until the fifth postoperative day, when the mediastinum had stabilized, to avoid postpneumonectomy syndrome. On postoperative day 6, arterial blood gases were pO₂ at 150 mm Hg, pCO₂ at 48 mm Hg, and pH at 7.42, under assisted ventilation with 35% of inspired oxygen fraction. Extubation was then attempted but reintubation became quickly necessary because of inefficient ventilation. A tracheotomy was performed the day after, which allowed complete weaning from the ventilator 22 days later. One episode of rejection was treated on postoperative day 10 with high dosage steroids. Forty-five days after transplant the computed tomographic scan showed a small consolidation of left lower lobe with perilesion ground glass. These lesions were related to a pseudomonas infection and were successfully treated by a course of intravenous Meropenem. The patient was discharged from the hospital on postoperative day 93 with improved lung function (forced expiratory volume in one second of 0.9 L and forced vital capacity of 0.95 L). Subsequent outpatient reviews up to 8 months have revealed improved forced expiratory volume in one second of 1.20 L, forced vital capacity of 1.33 L, and a 6-minute walk of as much as 600 m. Blood gas analysis on room air showed oxygen tension of 82 mm Hg and carbon dioxide tension of 42 mm Hg. Transbronchial biopsy specimens showed no more than grade A1 rejection. The computed tomographic scan showed that her mediastinum had shifted to the right and the pneumonectomy space was completely filled (Fig 3).

Comment

In this case, double lung transplantation would have been a better option. However there are no clinic characteristics among LAM patients that would favor the




Fig 2. Anatomical view of the native lung.

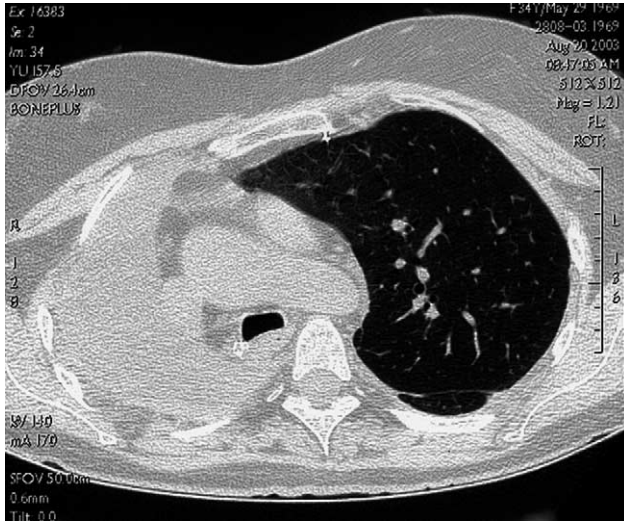


Fig 3. Chest computed tomographic scan 8 months after transplant.

double lung transplantation. Left single lung transplantation was scheduled because of the risk of bleeding after the total right pleurectomy and the absence of clinical respiratory infections. Moreover her clinical conditions pushed us to perform the single lung transplant in the effort of reducing the wait time [6]. The weaning from the ventilator was delayed. This was probably related to the hypoventilation of the lung in the first postoperative day due to her muscular weakness. We paid a lot of attention to avoid possible postpneumonectomy syndrome. This is more frequent after a right pneumonectomy in young patients in which the bronchus is softer and more compressible as in this case [7]. In our opinion, the risk of a right pleural space infection due to the balance drainage for 5 days is lower compared with the risk of postpneumonectomy syndrome without this type of drainage.

This case confirms that after single lung transplantation for end-stage LAM, the native lung is prone to develop complications that are difficult to treat. Single lung transplantation and bilateral pneumonectomy, if necessary, can be a valid option in case of end-stage respiratory failure from LAM as in cases of other lung diseases (ie, emphysema, cystic fibrosis) previously successfully treated by this surgical approach. However, the safety of the procedure in patients with any type of bacterial or fungi colonization should be verified considering the high percentage of complications reported in the literature for standard pneumonectomy in these cases [8].

References

1. Kitaiki M, Nishimura K, Itoh H, Izuni T. Pulmonary lymphangiomyomatosis: a report of 46 patients including a clinicopathologic study of prognostic factors. *Am J Respir Crit Care Med* 1995;151:527-33.
2. Bradley SL, Dines DE, Soule EH, Muhm JR. Pulmonary lymphangiomyomatosis. *Lung* 1980;158:69-80.
3. Sleiman C, Mal H, Jebrak G, et al. Pulmonary lymphangiomyomatosis treated by single lung transplantation. *Am Rev Respir Dis* 1992;145:964-6.
4. Rju JH, Doerr CH, Fisher SD, Olson EJ, Sahn SA. Chylothorax in lymphangiomyomatosis. *Chest* 2003;123(2):623-7.
5. Boehler A, Speich R, Russi EW, Weder W. Lung transplantation for lymphangiomyomatosis. *N Engl J Med* 1996;335:1275-80.
6. Hosenpud JD, Bennett LE, Keck BM, et al. The registry of the International Society for Heart and Lung Transplantation: 18th official report, 2001. *J Heart Lung Transplant* 2001;20:805.
7. Sakiyalak P, Vigneswaran WT. Postpneumonectomy syndrome in single lung transplantation recipient following previous pneumonectomy. *Ann Thorac Surg* 2003;75:10.
8. Deschamps C, Bernard A, Nichols FC, et al. Empyema and bronchopleural fistula after pneumonectomy: factor affecting incidence. *Ann Thorac Surg* 2001;72(1):243-7.

Pulmonary Sclerosing Hemangioma With Metastasis to the Mediastinal Lymph Node

Hiromichi Katakura, MD,
Manami Sato, MD, Fumihiko Tanaka, MD,
Hiroaki Sakai, MD, Toru Bando, MD,
Seiki Hasegawa, MD, Yasuaki Nakashima, MD, and
Hiromi Wada, MD

Department of Thoracic Surgery, Kyoto University, Kyoto, Japan

During a routine health care evaluation, an abnormal shadow was detected in the chest roentgenogram of a 35-year-old man. Chest computed tomography scanning showed a nodule, approximately 3 cm in diameter, in the left S6 pulmonary segment with surrounding infiltration. Bronchoscopy revealed obstruction of the left B6c bronchus by a tumor, for which biopsy was done but no definitive histologic diagnosis could be made. Then, left lower lobectomy was performed, and the tumor was diagnosed as a pulmonary sclerosing hemangioma. A mediastinal lymph node (no. 7) showed some metastatic tumor cells. As lymph node metastasis from pulmonary sclerosing hemangioma is very rare, we herein report the details of our case.

(Ann Thorac Surg 2005;80:2351-3)

© 2005 by The Society of Thoracic Surgeons

Since pulmonary sclerosing hemangioma was first reported by Liebow and Hubbell [1] in 1956, this disease has been thought to be derived from endothelial cells because of its rich vascularity. Recently, however, various diagnostic modalities, for example, immunohistochemistry and electron microscopy, have been developed, and this disease is now accepted as an epithelial neoplasm derived from the primitive respiratory epithelium, incompletely differentiated type II pneumocytes, or Clara cells [2, 3].

Accepted for publication June 16, 2004.

Address correspondence to Dr Wada, Department of Thoracic Surgery, Kyoto University, Sakyo-ku, Shogoin, Kawahara-cho, Kyoto 606-8507, Japan; e-mail: wadah@kuhp.kyoto-u.ac.jp.

Urgent Contralateral Pneumonectomy After Single Lung Transplantation for Lymphangioliomyomatosis

Luca Voltolini, Luca Luzzi, Piero Paladini, Bonizella Biagioli, Paola Rottoli and Giuseppe Gotti

Ann Thorac Surg 2005;80:2349-2351
DOI: 10.1016/j.athoracsur.2004.07.089

Updated Information & Services

including high-resolution figures, can be found at:
<http://ats.ctsnetjournals.org/cgi/content/full/80/6/2349>

References

This article cites 8 articles, 4 of which you can access for free at:
<http://ats.ctsnetjournals.org/cgi/content/full/80/6/2349#BIBL>

Subspecialty Collections

This article, along with others on similar topics, appears in the following collection(s):

Lung - transplantation
http://ats.ctsnetjournals.org/cgi/collection/lung_transplantation

Permissions & Licensing

Requests about reproducing this article in parts (figures, tables) or in its entirety should be submitted to:

<http://www.us.elsevierhealth.com/Licensing/permissions.jsp> or
email: healthpermissions@elsevier.com.

Reprints

For information about ordering reprints, please email:
reprints@elsevier.com



THE ANNALS OF THORACIC SURGERY

